Early prosthodontic intervention on two three-year-old twin girls with ectodermal dysplasia

L. W. Ou-Yang, T. Y. Li, A. I. Tsai

Department of Paediatric Dentistry, Chang-Gung Memorial Hospital, Taoyuan, Taiwan

e-mail: minamy6567@gmail.com

DOI 10.23804/ejpd.2019.20.02.11

Abstract

Background Early prosthodontic treatment for cases of ectodermal dysplasia (ED) is usually difficult because of oligodontia, undeveloped alveolar ridges, and the young age of the patients. Although some cases of prosthetic management of ED patients have been reported in the literature, there have been few cases about prosthetic treatment in children younger than 5 years of age.

Case report This case report presents early prosthetic oral rehabilitation of 2 twin sisters with ectodermal dysplasia and severe hypodontia in the primary dentition. Fixed partial dentures with bands retained on deciduous molars were fabricated when the girls were 3 years old. New flexible removable partial dentures were made when the girls turned 6 years to accommodate the ongoing alveolar development. After the dental treatment, the two girls' aesthetics, phonetics, and chewing functions all improved significantly, which in turn raised the girls' self-esteem and increased their overall quality of life.

Conclusion These two cases demonstrated that properly timed and managed early prosthodontic intervention can improve the overall life quality of young patients with ectodermal dysplasia.

KEYWORD Craniofacial anomalies; Dental prosthesis design; Ectodermal dysplasia.

Introduction

Ectodermal dysplasia (ED) is a group of rare disorders characterised by abnormal development of two or more embryonic ectoderm derivatives such as skin, hair, nail, sweat gland, tooth, and other organs. To date, more than 190 distinct disorders have been recognised [Itin and Fistarol, 2004]. All Mendelian modes of inheritance related to ED—autosomal dominant and recessive, X-linked dominant and recessive—have been described. Systemic symptoms of ED include sparse hair or alopecia, nail dystrophy, dry and hypopigmented skin, and dysfunction of sweat glands that often results in high fever.

Intraoral manifestations of ED include anomalies in tooth number (partial or complete absence of primary and permanent dentitions), morphology (conical or malformed teeth), and structure (enamel hypoplasia) [Bergendal, 2014]. The absence of teeth may result in poor development of the alveolar bone. Some patients also have cleft lip and palate.

Patients with ED often suffer from alterations in the craniofacial complex as well. Cephalometric studies have found that maxillary retrusion and forward and upward rotation of the mandible contribute to reduced vertical facial height and Class III malocclusion [Vierucci et al., 1994; Johnson et al., 2002]. Suboptimal bone growth makes ED patients appear older than their age, due to reduced vertical facial height, increased nasolabial folds, and a flattened face.

Prosthetic solutions for ED patients include removable or fixed partial dentures, complete dentures, and implant-retained prostheses. The objective of prosthetic treatment is to fit patients with a functional prosthesis that is well-retained, stabile, and properly-supported, so that the patients' chewing and phonetic functions, facial appearance, and even self-esteem can improve. Although some cases of prosthetic management of ED patients have been reported in the literature, there have been few cases about prosthetic treatment in children younger than 5 years of age. This case report presents early prosthetic oral rehabilitation of 2 twin sisters with ectodermal dysplasia and severe hypodontia in the primary dentition.

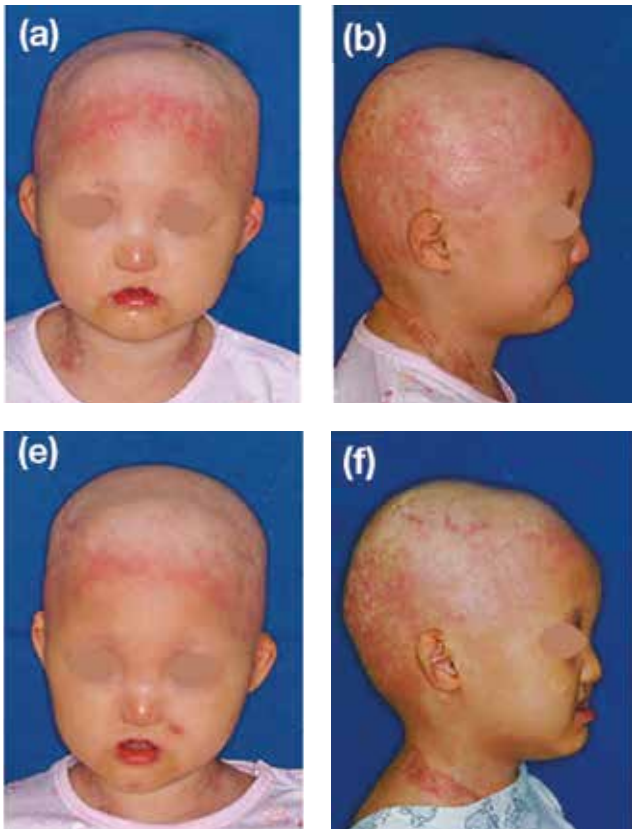

FIG. 1 Facial and intraoral photographs before the prosthodontic intervention. The elder (a-d) and the younger sister (e-h).

FIG. 2 Facial and intraoral photographs after the prosthodontic intervention (3 years old). The elder (a-d) and the younger sister (e-h).

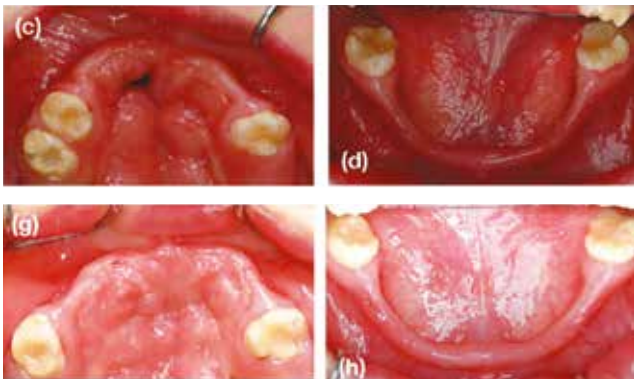

Case report

Two 3-year-old twin girls with ED were referred to our department for prosthetic evaluation. The parents were concerned about the poor aesthetics and the difficulty two girls experienced with chewing and speaking. Both girls could only consume liquids and soft food.

The twin girls were diagnosed of sporadic ectrodactyly-ectodermal dysplasia-clefting (EEC) syndrome at birth. EEC syndrome is a congenital anomaly characterised by ectodermal dysplasia, ectrodactyly, cleft lip and palate, and lacrimal duct anomalies. Both girls exhibited typical features of ED: skin, hair, and nail anomalies, and mild hypofunction of the sweat gland. Scarred nasolacrimal ducts were observed, and the younger sister had missing toes on her right foot. They both received craniofacial surgery for cleft palate at the age of 1 year, although the elder sister still had an oroantral fistula over her upper palate.

Clinical and radiographic examinations revealed that all primary incisors and canines were absent. The girls had a few malformed deciduous molars with hypoplastic enamel and large carious lesions in both arches (Fig. 1). Deficient edentulous alveolar ridges in both height and width were also observed. Cephalometric films revealed retruded maxilla and upward and forward rotated mandible which contributed to reduced lower anterior facial height and Class III malocclusion (Fig. 4a). The reduced vertical occlusal dimension made the girls look older than their age.

Due to the absence of anterior abutment teeth and the flat alveolar ridge of the two girls, it would be difficult to achieve proper retention and stability of a removable partial denture. Hence, after the discussion with the parents, fixed partial dentures with stainless-steel bands extended from the denture base and retained on all

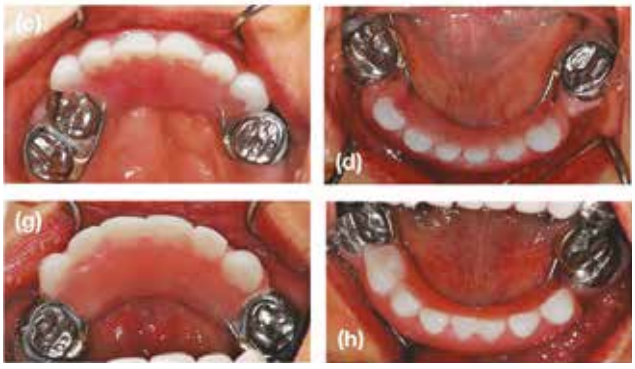

FIG. 3 Intraoral photographs after the prosthodontic intervention (6 years old). The elder (a-b) and the younger sister (c-d).

deciduous molars were planned, instead.

When the diagnostic impression was made, the twin girls were too young to be fully cooperative. Nonetheless, both parents and patients remained committed to the dental prosthesis treatment. One month later, with the patients under general anaesthesia, stainless steel crowns were fabricated to restore all carious molars without pulp treatment. The final impression for the denture was made during the same visit. Occlusal rims were fitted and jaw relation records were made during a separate visit.

After the insertion of dentures, both the patients and the parents were pleased with the aesthetic improvement attributable to the increased occlusal vertical dimension and adequate lip support (Fig. 2). The twin girls adapted well to the dentures and started consuming solid food such as small pieces of vegetable and meat. They also started receiving phonetic therapy and saw noticeable improvement. The band-retained partial dentures were removed for cleaning during monthly follow-up visits.

Two years later, the dentures no longer fit properly due to the development of the alveolar arch. The dentures were then relined for better tissue adaptability.

New removable partial dentures were fabricated when the girls were 6 years old. Three malformed permanent first molars had erupted by that time, and hypoplastic enamel and gross decay were soon found on some permanent molars. Therefore, stainless steel crowns were fitted to the hypoplastic molars for tooth restoration and better retention of dentures. The flexible removable partial dentures were designed to encircle all deciduous and permanent molars. After the final impression and jaw relation records were made, new dentures were inserted before the girls entered the elementary school (Fig. 3). The twin girls and their parents were instructed to remove and clean the prosthesis after every meal. Follow-up appointments were scheduled for every 2 months to monitor the mucosal tissue status and for possible occlusal discrepancies as the girls grew.

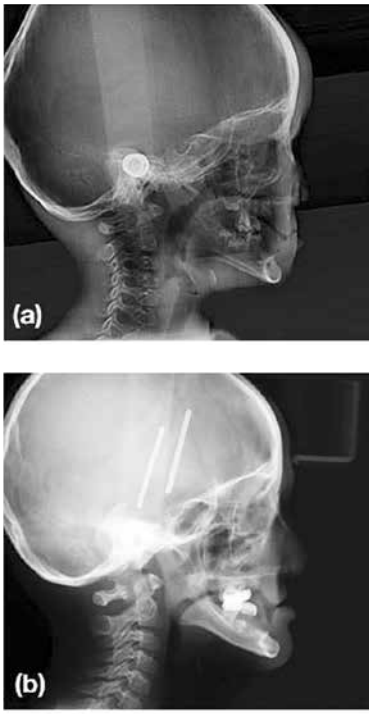

FIG. 4 Cephalometric films of the elder sister before the prosthodontic intervention (3 years old) (a) and 5 years after the prosthodontic intervention (8 years old) (b).

Discussion

Early prosthodontic intervention can help ED children to develop normal speech, chewing, and swallowing functions; provide better facial support, and improve the temporomandibular joint function. Psychosocial benefits after prosthodontic interventions have also been reported [Hickey and Salter, 2006]. Hence, it is recommended that such treatment start when children are 2 to 3 years old [Hickey and Salter, 2006; Hickey and Vergo, 2001]. However, early placement of multiple implants is not suitable for partially edentulous ED children due to the ongoing development of their jaws. Although removable dentures appear a viable transitional option, insufficient bone support and the amorphous tooth shape may negatively affect retention and stability of dentures. Therefore, in the present two cases, bands retained on primary molars were designed to provide better retention for the dentures. Three years later, flexible removable partial dentures were remade to encircle all the primary molars and the newly-erupted permanent molars. As the ED child grows, removable dentures need to be relined or remade to accommodate growth-related dentoskeletal changes. In general, prostheses need to be relined every 2 to 4 years and remade every 4 to 6 years [Vergo, 2001].

During the dental fabrication, the correct vertical dimension is determined at the physiological rest position as the patient's facial support is observed. In the current cases, cephalometric films were taken before the denture fabrication as well as 2 and 5 years after the denture insertion (Fig. 4). Cephalometric analysis was performed to evaluate for any growth-related changes. The cleft palate and the lack of dentition were believed to have caused the retrusion of maxilla [Birgfeld et al., 2007; Okamura et al., 2013]. With the insertion of dental prosthesis, the facial soft tissue harmony, especially as related to the cant of upper lip, improved significantly. The size of mandibular ramus and body was within the normal range. The facial axis angle decreased from 98° to 95°, more in line with the expected mandibular growth than before the treatment. Hence, our findings supported the conclusions by Bhalla et al. [2013] and Frahchi et al. [1998] that inserting a dental prosthesis when children are young could prevent the development

of Class III jaw relationship and facilitate normal skeletal development as children grow.

While reviewing psychological literature on craniofacial anomalies, Endriga and Kapp-Simon [1999] found that 30%-40% of ED children experienced difficulties such as internalising (shyness, depression, somatisation) and/or externalising (disobedience, fight, and impulsivity) problems, learning disorders, and compromised social competence. After the prosthetic treatment, the 2 girls started receiving phonetic therapy. Improved aesthetics and pronunciations in turn raised the girls' self-esteem. The 2 girls could also eat normal meals at school like thr other students, and exhibited no behavioural problems such as social withdrawal or peer rejection.

For young ED patients, the timing for implant placement can be challenging as inserted implants may act like ankylosed teeth. For partially edentulous patients, the implant insertion should be performed in their late teens [Bryant, 1998]. In cases of anodontia and severe oligodontia, implants can be inserted earlier [Imirzalioglu et al., 2002; Klineberg et al., 2013]. A consensus meeting on rehabilitation of ED children was held in 2013 where expert teams from 6 countries agreed that the earliest age for implant treatment should be the age of 7 or 8 years for the anterior mandible and older for the maxilla [Klineberg et al., 2013]. The timing for implant insertion should be determined according to the patients' maxillofacial development, local alveolar bone growth, and their dentitions at the time.

Early prosthodontic treatment for ED cases is usually difficult because of oligodontia, undeveloped alveolar ridges, and the young age of the patients. The current 2 cases demonstrated that properly timed and managed early prosthodontic intervention can improve the overall life quality of young ED patients.

Consent

A written informed consent was obtained from patients' legal guardians for publication of this case report and accompanying images.

References

- Bergendal B. Orodental manifestations in ectodermal dysplasia-a review. Am J Med Genet 2014;164A:2465-71.
- Bhalla G, Agrawal KK, Chand P, et al. Effect of complete dentures on craniofacial growth of an ectodermal dysplasia patient: a clinical report. J Prosthodont 2013;22:495-500.
- Birgfeld CB, Glick P, Singh D, LaRossa D, Bartlett S. Midface growth in patients with ectrodactyly-ectodermal dysplasia-clefting syndrome. Plast Reconstr Surg 2007;120:144-50.
- Bryant SR. The effects of age, jaw site, and bone condition on oral implant outcomes. Int J Prosthodont 1998;11:470-90.
- Endriga MC, Kapp-Simon KA. Psychological issues in craniofacial care: state of the art. Cleft Palate Craniofac 1999;J 36:3-11.
- Franchi L, Brahchi R, Tollaro I. Craniofacial changes following early prosthetic treatment in a case of hypohidrotic ectodermal dysplasia with complete anodontia. ASDC J Dent Child 1998;65:116-21.
- Hickey AJ, Salter M. Prosthodontic and psychological factors in treating patients with congenital and craniofacial defects. J Prosthet Dent 2006;95:392-6.
- Hickey AJ, Vergo TJ, Jr. Prosthetic treatments for patients with ectodermal dysplasia. J Prosthet Dent 2001;86:364-8.
- Imirzalioglu P, Uckan S, Haydar SG. Surgical and prosthodontic treatment alternatives for children and adolescents with ectodermal dysplasia: a clinical report. J Prosthet Dent 2002;88:569-72.
- Itin PH, Fistarol SK. Ectodermal dysplasias. Am J Med Genet C Semin Med Genet 2004;131C:45-51.
- Johnson EL, Roberts MW, Guckes AD, et al. Analysis of craniofacial development in children with hypohidrotic ectodermal dysplasia. Am J Med Genet 2002;112:327-34.
- Klineberg I, Cameron A, Hobkirk J, et al. Rehabilitation of children with ectodermal dysplasia. Part 2: an international consensus meeting. Int J Oral Maxillofac Implants 2013;28:1101-9.
- Klineberg I, Cameron A, Whittle T, et al. Rehabilitation of children with ectodermal dysplasia. Part 1: an international Delphi study. Int J Oral Maxillofac Implants 2013;28:1090-100.
- Okamura E, Suda N, Baba Y, et al. Dental and maxillofacial characteristics of six Japanese individuals with ectrodactyly-ectodermal dysplasia-clefting syndrome. Cleft Palate Craniofac J 2013;50:192-200.
- Vergo TJ, Jr. Prosthodontics for pediatric patients with congenital/developmental orofacial anomalies: a long-term follow-up. J Prosthet Dent 2001;86:342-7.
- Vierucci S, Baccetti T, Tollaro I. Dental and craniofacial findings in hypohidrotic ectodermal dysplasia during the primary dentition phase. J Clin Pediatr Dent 1994;18:291-7.