

# Vertical relapse after orthodontic and orthognathic surgical treatment in a patient with myotonic dystrophy



G.S. Antonarakis,  
G. Herzog, S. Kiliaridis

*\*Division of Orthodontics, University  
Clinics of Dental Medicine,  
University of Geneva, Switzerland*

*gregory.antonarakis@unige.ch*

DOI 10.23804/ejpd.2019.20.01.11

## Abstract

Patients with myotonic dystrophy (MD), a neuromuscular multisystem disease characterised by progressive muscular weakness, often present with an anterior open bite associated with excessive facial vertical development. These aberrations in vertical craniofacial growth may be due to the reduced function of the masticatory muscles and the lowered position of the tongue. Well-planned and executed treatment of these patients, with orthodontics and orthognathic surgery, can provide satisfactory results. The long-term stability of these treatment results however remains undocumented. This paper describes a case of severe anterior open bite in a patient with MD treated with orthodontics and orthognathic surgery, with an acceptable post-treatment result. Long-term follow-up however revealed a highly unstable outcome. Reasons for this include the continued overeruption of posterior teeth due to the weakened masticatory musculature, mandibular posture, or problems with TMJ adaptation and remodeling. Possible ways to minimise this instability are discussed, namely lifelong skeletal retention or postponing treatment until a later age.

## Introduction

Myotonic dystrophy (MD) is a neuromuscular multisystem disease characterised by progressive muscular weakness, known as myotonia [Russell and Hirsch, 1994]. Its estimated incidence is roughly 1 in 8,000, being the most common form of muscular dystrophy [Harper, 2001]. The inheritance of MD is autosomal dominant with variable expressivity but complete penetrance. Two distinct forms of MD have been defined, type 1 and type 2, based on different unstable nucleotide repeat expansions in untranslated DNA, with type 1 being the most commonly occurring and caused by the expansion of an unstable trinucleotide (CTG) repeat sequence in a region of the myotonic dystrophy kinase gene [Turner and Hilton-Jones, 2014]. MD type 1 consists of five clinically defined phenotypes based on age of onset and CTG repeat size, namely congenital, childhood onset, classical (adult onset), mild, and permutation [Turner and Hilton-Jones, 2014].

One of the earliest and most constant features of MD is facial weakness, with an expressionless face, sagging cheeks, and severe ptosis of the eyelids [Harper, 2001]. The masticatory muscles are affected, and one can detect thinner masticatory muscles with loss of internal muscle structure) [Kiliaridis et al., 1989; Kiliaridis et al., 1995; Zanolini et al., 2002; Tieleman et al., 2012]. The atrophy of the masseter muscles and the muscle fibre replacement in patients with MD may lead to a decreased maximal molar bite force and reduction in electromyographic muscle activity during maximal clenching and chewing [Odman and Kiliaridis, 1996; Guimaraes et al., 2007; Memoto et al., 2009].

Dentofacial findings in individuals with MD include increased lower facial height, lip incompetence, a high palatal arch, a steep mandibular plane, transverse maxillary deficiency, dental crowding, and an anterior open bite [Kiliaridis et al., 1989; Staley et al., 1992; Portelli et al., 2009]. It is postulated that the development of malocclusion among patients with MD is related to vertical aberrations in craniofacial growth due to reduced function of the masticatory muscles, and the lower position of the tongue and the mandible [Kiliaridis and Katsaros, 1998], leading

**KEYWORDS** Myotonic Dystrophy; Myotonia; Open bite; Vertical Growth.

to muscular imbalance and the resultant occlusal and facial aberrations. The combination of the lowering of the mandible and relative decrease in bite force permits the overeruption of posterior teeth and the development of anterior open bite [Kiliaridis and Katsaros, 1998], which can be severe.

Due to the severity of the malocclusion and dentofacial deformity present, as well as possible functional limitations resulting in impairments in daily living, orthognathic surgery can be considered in some patients with MD [Bezak et al., 2016]. Orthognathic surgery can play an important role in the management of congenital or acquired deformities of the facial skeleton [Manzon and Philbert, 2007], especially in cases where, due to the magnitude of the discrepancy, the aesthetic and functional goals of treatment are not achievable with conventional orthodontics alone.

Patients with MD however present certain particularities that may complicate the task of deciding whether orthognathic surgery will be proposed as a viable treatment option. One must consider both the benefits and risks of such a procedure. In this population, the potential risks of an elective surgery and general anaesthesia may outweigh the benefits of carrying out such procedures [Manzon and Philbert, 2007]. Moreover, the indication to propose orthodontic treatment and orthognathic surgery to improve aesthetics and masticatory function is difficult to determine since the progressive nature of MD implies that the prognosis with regard to the development of dentofacial abnormalities and the outcome and stability after a certain treatment remains unpredictable [Balasubramaniam et al., 2008].

Despite this, the psychosocial effect related to aesthetics and facial appearance may also be a factor influencing the treatment decision process [Bezak et al., 2016]. The importance of aesthetics cannot be overlooked for teenagers and young adults who are often defined and limited by the physical manifestations of their deformity [Phillips and Beal, 2009; Marik and Hoag, 2012]. Considering that the treatment can result in a significant improvement in facial aesthetics, jaw function, self-esteem and quality

of life, these situations may lower the threshold in favour of orthognathic surgery in selected patients [Manzon and Philbert, 2007; Bezak et al., 2016].

With this in mind, the complexity of the disease, the perioperative morbidity that can accompany MD, and the unpredictability of treatment dictate the need for a thorough evaluation from a multidisciplinary team when planning a combined orthodontic and orthognathic surgical intervention [Manzon and Philbert, 2007]. The individuals involved must be knowledgeable of the disease process, the physical characteristics and the concomitant systemic abnormalities which help facilitate proper planning, timely interventions, and efficient postoperative care.

The body of the maxillofacial and orthodontic literature is scarce with regard to orthodontic and orthognathic surgical management of patients with MD. A limited number of cases have appeared in the literature over the past 35 years. To the best of our knowledge, one case with camouflage orthodontic treatment [Thind and Turbill, 2015] and 9 cases with combined orthodontic and orthognathic surgical treatment [Müller and Punt-van Manen, 1982; Kaufman et al., 1983; Manzon and Philbert, 2007; Bezak et al., 2016] have been reported. These are presented in Table 1. Amongst these cases however only two refer to a long-term follow-up (12 and 18 months, respectively). In both cases it is reported that the occlusion was stable with an improvement in facial harmony. It is not clear however when orthodontic treatment was terminated, since the authors refer to a postoperative and not a post-treatment follow-up and it could well be that the postoperative orthodontic phase lasted for the greatest part of this postoperative follow-up period. In addition, records shown are incomplete without a lateral cephalometric radiograph immediately postoperatively and after the 12–18 month follow-up to assess skeletal and dental stability.

The purpose of the current case is to present the first case in the literature of a radiographically well-documented long-term follow-up of a patient with MD undergoing a combined orthodontic and orthognathic surgical treatment,

Year	Authors	Patient age	Sex	Type of MD	Malocclusion	Tooth extractions	Orthognathic surgery	Orthodontics	Follow-up
1982	Müller and Punt-van Manen	19	M	unspecified	AOB	-	Mandible	FA	none
		16	M	unspecified	AOB	-	Bimaxillary	FA	none
		20	F	unspecified	AOB	-	Bimaxillary	FA	none
		17	M	unspecified	AOB	-	Mandible	FA	none
1983	Kaufman et al.	26	M	unspecified	Class III; AOB tendency	4 premolars	Bimaxillary + Genio	FA	12 months postop
2007	Manzon and Philbert	15	F	Type 1	AOB	-	Bimaxillary	FA	18 months postop
2015	Thind and Turbill	11	F	Type 1	Class II; AOB tendency	-	none	TB, HPHG; FA	none
2016	Bezak et al.	15	F	Type 1	Class III; AOB	-	Bimaxillary	FA	none
		18	M	Type 1	Class II; AOB	-	Bimaxillary	FA	none
		19	M	Type 1	Class III; AOB	-	Maxillary	FA	none

**TABLE 1** Published case reports or case series of orthodontic treatment with or without orthognathic surgery in patients with myotonic dystrophy. Abbreviations: AOB = anterior openbite; F = female; FA = fixed appliances; genio = genioplasty; HPHG = high-pull headgear; M = male; postop = postoperative; TB = twinblock.

and the problems encountered with maintaining a stable dental occlusion in these cases.

### Case report

A 17-year-old male patient with MD type 1 presented to an orthodontic practice in Switzerland, dissatisfied with his facial appearance and with difficulties in properly chewing food and closing his mouth. He complained also of the lack of tooth to tooth contact. Extraoral examination revealed a long, tapered face, increased middle and lower facial thirds, lip incompetence and mentalis muscle strain. A convex profile and short mandibular length were also noted. Intraoral examination (Fig. 1) showed an intact dentition up to and including the second permanent molars, without evidence of carious lesions. There was a severe anterior open bite (13 mm), a constricted maxillary dental arch with an associated posterior crossbite and a high palatal vault. There was moderate mandibular incisor crowding. In maximal intercuspitation, the only teeth in contact were the molars. The sagittal relationship of the molars was Class I on the right but Class III on the left side.

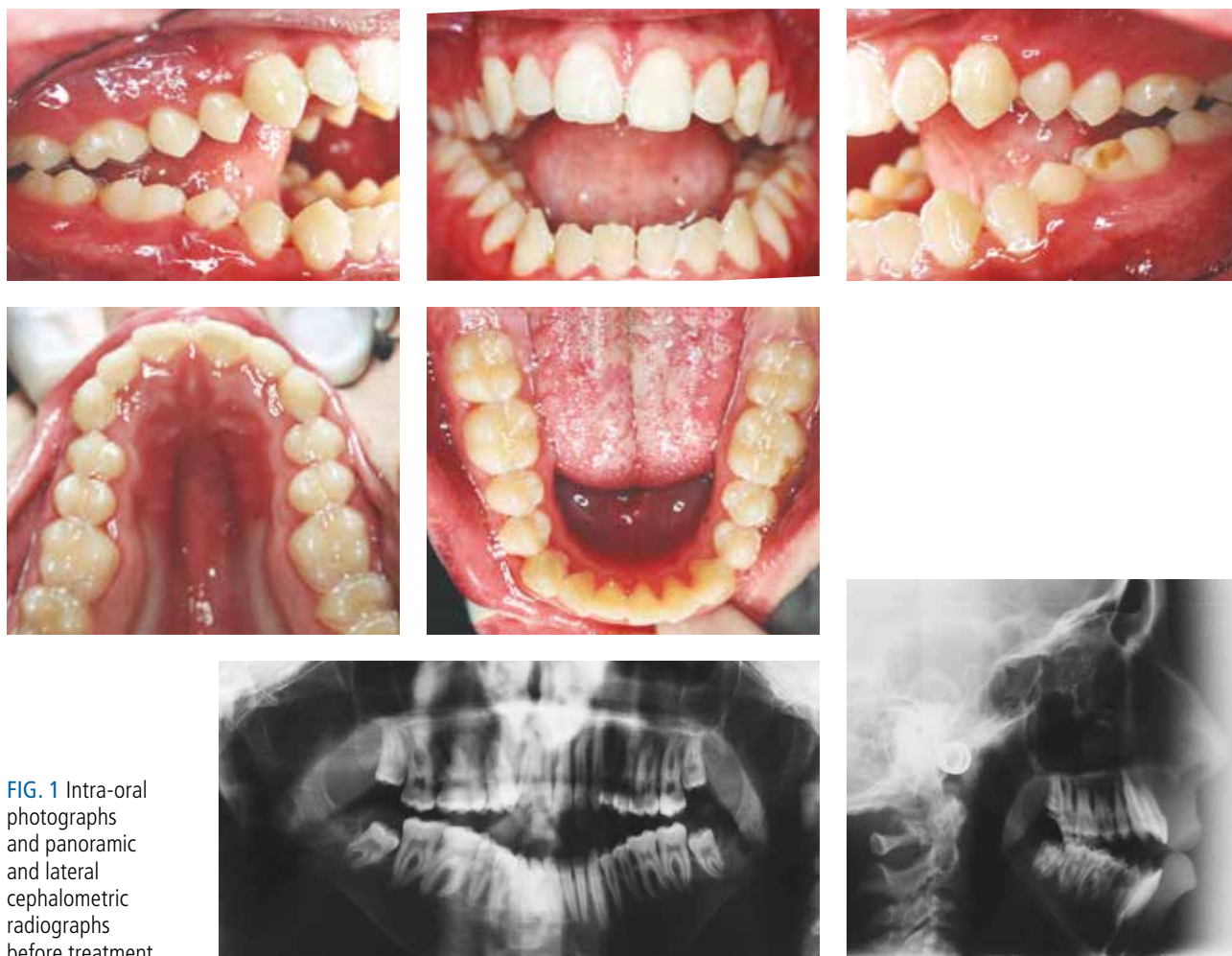
Radiographic examination (Fig. 1 G) revealed the presence of unerupted third molars. Cephalometric evaluation confirmed a highly hyperdivergent skeletal pattern with an obtuse gonial angle and large anterior facial height, but normal sagittal skeletal relationships despite bimaxillary

retrognathia. The lower incisors were retroclined.

Treatment options were discussed with the patient and family. The informed consent process included individualised discussions of each treatment option, including orthognathic surgery, and its associated risks and benefits. The reasons for carrying out surgery were balanced with the risks of surgery and general anaesthesia in this medically complex patient. The surgeon, orthodontist, and patient carefully considered the benefits and risks of the surgical intervention. The medical and anaesthetic risks presented relative contraindications to surgery in general, although compelling reasons to operate overcame these contraindications in this case.

The primary goals of the combined orthodontic and orthognathic surgical treatment were to close the anterior open bite by reducing the posterior vertical maxillary excess and thus the facial height, resulting in a positive post-treatment overbite. This would be done by carrying out a bimaxillary osteotomy comprising maxillary advancement with posterior impaction, allowing for mandibular autorotation combined with mandibular setback.

Orthodontic levelling and aligning, as well as orthodontic decompensation was carried out using 022-slot self-ligating fixed appliances and Class II intermaxillary elastics. The pre-surgical orthodontic preparation took 12 months. Corrective orthognathic surgery was carried out under general anaesthesia. Rigid skeletal fixation was utilised for stabilisation of the maxillary and mandibular osteotomies.



**FIG. 1** Intra-oral photographs and panoramic and lateral cephalometric radiographs before treatment.

Immediate postoperative follow-up revealed good soft tissue healing and occlusion remained stable. No surgical complications were identified. Following orthognathic surgery, orthodontic finishing took another 6 months, before debonding and the insertion of removable retention appliances. Total treatment time was 18 months.

Treatment results were satisfactory, with well distributed intermaxillary occlusal contacts and a positive overjet and overbite (Fig. 2). The patient reported satisfaction with the treatment result and improved control of oral secretions, facial and jaw function, masticatory efficiency and nutrition, and even decreased psychosocial stress during the immediate follow-up period, although these outcomes were not quantified in any way.

The patient was reviewed periodically following the end of active orthodontic treatment. One year post-treatment, signs of relapse were evident with the overbite beginning to progressively decrease. Within a few years post-treatment, an anterior open bite was once again well-established. The 4-year post-treatment clinical examination revealed a Class III malocclusion with negative overjet, a posterior crossbite, and a severe anterior open bite (7 mm). Intermaxillary occlusal contacts were only present on the third molars. Subsequent to this, the third molars were extracted in an attempt to reduce the anterior open bite. At 13.5 years post-treatment (Fig. 3), examination revealed a Class III malocclusion with negative overjet, a posterior crossbite, and an anterior open

bite (9 mm) with intermaxillary occlusal contacts present only on the second molars.

When evaluating the lateral cephalometric radiographs immediately after treatment as well and during the post-treatment follow-up, one can notice that the maxillary molars seem to move in a forward and downward direction. Therefore, this was evaluated radiographically using the maxillary rigid fixation plates as stable reference structures [Liou et al., 1998]. By superimposing the maxilla of the final treatment lateral cephalogram with post-treatment lateral cephalograms, the maxillary molars are found to erupt by roughly 6 mm throughout this 13.5-year period (Fig. 4). This is thus certainly one factor that may be partly responsible for relapse of the open bite.

In order to evaluate the possibility of condylar resorption being responsible for the relapse of the open bite, the height of the ascending ramus including the condylar process was evaluated radiographically on the immediate post-treatment and 13.5-year follow-up radiographs. No shortening of the ascending ramus was measured during this post-treatment period indicating that condylar resorption is not a likely culprit for the relapse.

**Discussion**

The present case is the first to display lack of long-term stability in a patient with MD type 1 treated with orthodontics

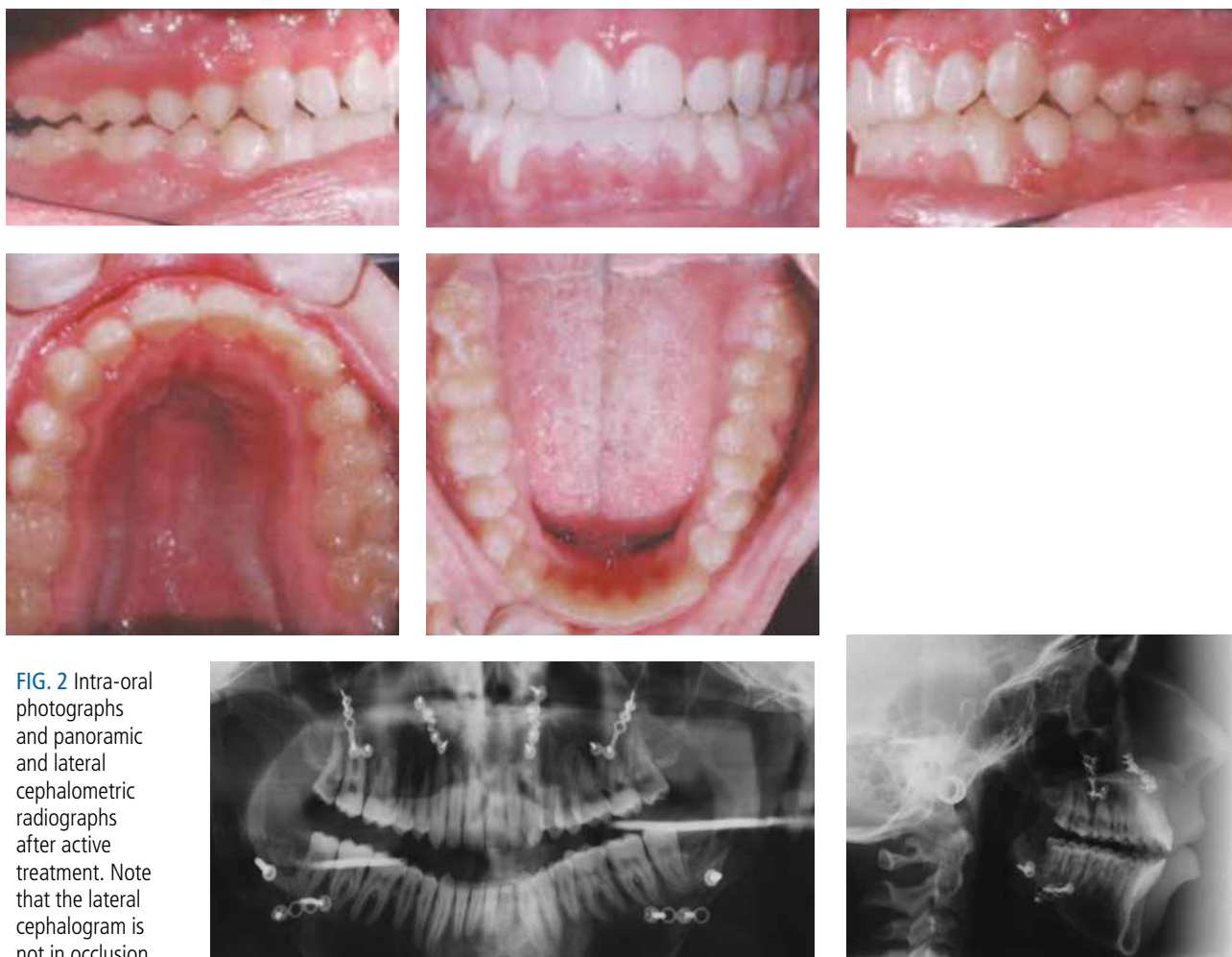


FIG. 2 Intra-oral photographs and panoramic and lateral cephalometric radiographs after active treatment. Note that the lateral cephalogram is not in occlusion.



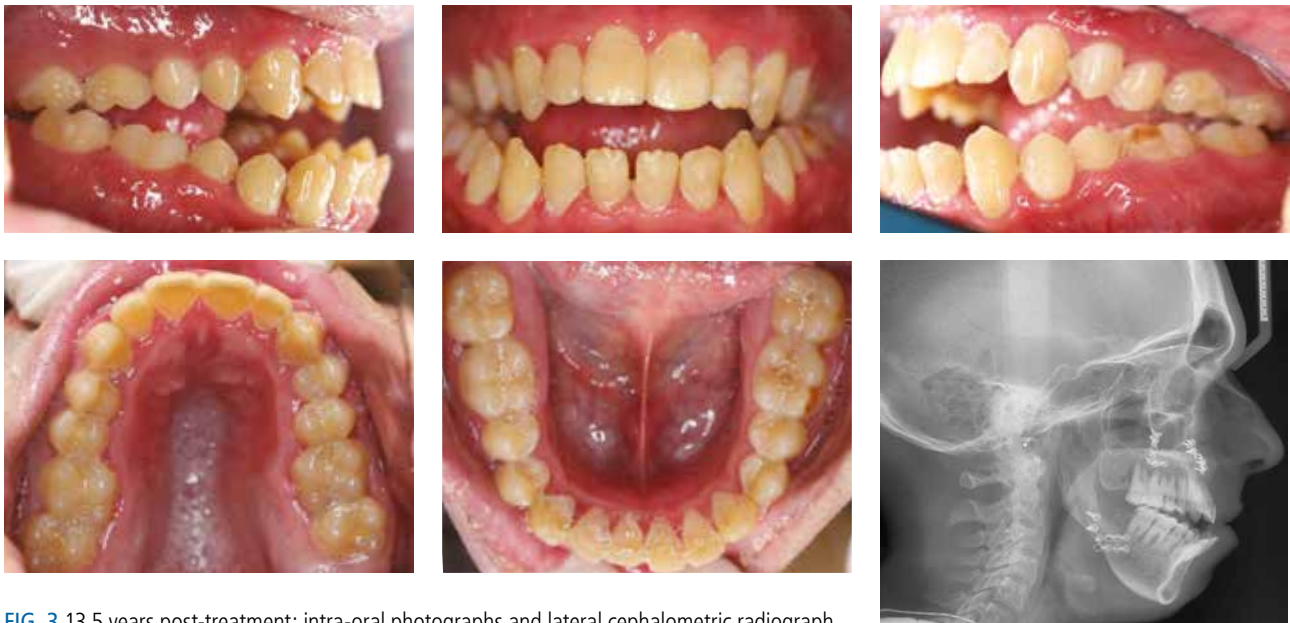

FIG. 3 13.5 years post-treatment: intra-oral photographs and lateral cephalometric radiograph.

and orthognathic surgery. Only one previously published case exists highlighting the difficulties in maintaining dentofacial stability in patients with muscular dystrophies. Although not of a patient with MD, the authors show a 16-year-old male patient with Becker muscular dystrophy treated with orthodontics, and even within 3 months of completing treatment to close the open bite, relapse was visible [Suda et al., 2004].

A treatment plan involving orthognathic surgery, coupled with multidisciplinary management, in patients with MD and associated dentofacial deformities can offer satisfactory aesthetic and functional outcomes with minimal morbidity. The question of whether this satisfactory result can remain stable in the long-term, however, is a question which is central to the treatment planning and decision making process.

When carrying out orthognathic surgery in these individuals, rigid fixation must be used and maxillomandibular fixation avoided to maintain patency of the upper airway and promote early return to function [Manzon and Philbert, 2007]. Orthognathic surgical movements must be designed to favor long-term skeletal stability because of the high relapse potential as a result of progressive weakness of the masticatory muscles [Manzon and Philbert, 2007]. Weakness of the masticatory muscles may result in immediate relapse of surgical movements to correct the anterior open bite or may present as a late complication due to the overeruption of both the maxillary and mandibular posterior dentition [Kaufman et al., 1983; Zanoteli et al., 2002; Manzon and Philbert, 2007]. The abnormal patterns of vertical facial growth, linked with altered neuromuscular function, may present difficulties for orthodontists and maxillofacial surgeons treating these patients [Staley et al., 1992].

Despite the weakness of the masticatory musculature and instability related to the overeruption of posterior teeth, another factor perhaps linked to relapse in patients with MD is related to the temporomandibular joint (TMJ). Zanoteli et al. [2002] showed that masticatory muscles are frequently and intensively affected in patients with MD, but they also found mild bone changes as frequent abnormalities

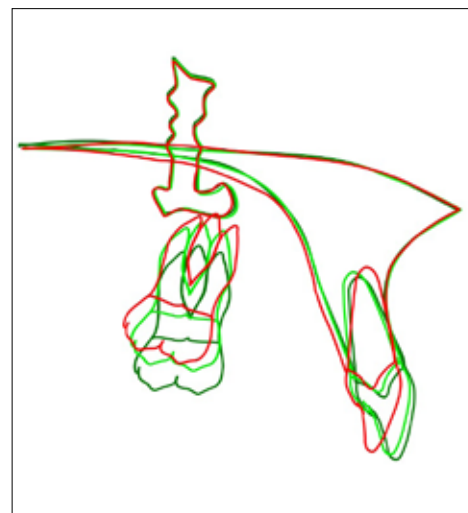


FIG. 3 Maxillary superimposition on maxillary rigid fixation plates of the immediate post-treatment lateral cephalogram (red), 4.5 years post-treatment (light green), and 13.5 years post-treatment (dark green) showing the changes in the position of the first maxillary molars.

observed in the TMJ. The TMJ changes encountered may perhaps be another factor related to the lack of stability following treatment involving orthognathic surgery. Condylar resorption could be another factor linked with relapse of the anterior open bite following orthognathic surgery, however this did not seem to be the cause in the present case.

The high potential for instability following orthodontic and orthognathic correction of an anterior open bite in patients with MD raises the issue of long-term retention. There is a critical need for long-term retention in these patients, and the treating orthodontist must evaluate the most appropriate way to provide retention so as to avoid the reappearance of an open bite. This may be with the use of a posterior bite-block, through its positive effect on the maxillary and mandibular molars, or elastics attached to skeletal anchorage plates that act on the maxillary and mandibular molars. As with any long-term retention protocol, compliance may be a challenging problem. This highlights the importance of

the informed consent, which must be properly obtained from the individual in question. If patients with MD chose to correct their dentofacial deformity, they must be aware that the result may only be stable for a limited time due to the high relapse potential, perhaps even despite any long-term lifelong retention protocols. One must always keep in mind that not undergoing any treatment also remains an option.

Regardless of which retention protocol is chosen in an attempt to favour long-term stability, chewing and mandibular exercises may also be of benefit. The adaptability of the healthy masticatory muscles to training, such as chewing exercises, has been demonstrated in healthy individuals [Ingervall and Bistanis, 1987; Kiliaridis et al., 1995; Georgiakaki and Kiliaridis, 1998; He et al., 2013]. Whether this is the case in individuals with MD and whether this would help in maintaining stability is however unknown. No studies have been carried out on patients with MD, but some data exists on patients with Duchenne muscular dystrophy where they find that masticatory exercises can improve masticatory function and performance in these patients [Kwazoe et al., 1982; Nozaki et al., 2010; van Bruggen et al., 2015]. By extrapolating these results, one may anticipate that chewing exercises in patients with MD may help prevent severe molar overeruption and thus diminish the chance of the reappearance of an anterior open bite. Specific research looking into this is nonetheless necessary.

A final point worth raising is that dentofacial deformities similar to the ones seen in patients with MD may also be seen in apparently healthy individuals. Relapse in these cases of anterior open bite in healthy individuals is also relatively common, with approximately 16% of those undergoing maxillary procedures and 12% of those undergoing bimaxillary procedures presenting with long-term relapse [Solano-Hernandez et al., 2013]. Care is also advised in these individuals with regard to the potential for instability for these reasons, and since some patients may seek orthodontic treatment for anterior open bite unaware that they are affected by MD [Mercier et al., 1995], and thus orthodontists as well as maxillofacial surgeons must be alert to this possibility. Postponing treatment in these individuals until a later age may decrease the risk of presenting with vertical relapse in the long-term. Delayed treatment ensures that the overeruption capacity of the posterior teeth, though still present, may be decreased [Kiliaridis et al., 2000].

## Conclusions

Problems with long-term vertical stability in a patient with MD treated with orthodontics and orthognathic surgery to correct his anterior open bite are presented. Lifelong skeletal retention or postponing treatment until a later age, are described as possible ways to minimise this lack of stability, and obtaining proper informed consent is stressed.

## Acknowledgements

The authors would like to acknowledge J. Bertrand (CHUV University Hospital Lausanne) who was responsible for the surgical care of the present patient, who sadly passed away a few years ago. We also would like to thank F. Egli (University of Geneva) who kindly helped with the cephalometric superimpositions.

## Conflict of interest statement

The authors report no conflicts of interest.

## References

- Balasubramaniam R, Sollecito TP, Stoopler ET. Oral health considerations in muscular dystrophies. *Spec Care Dentist* 2008;28:243-253.
- Bezak BJ, Arce KA, Jacob A, Van Ess J. Orthognathic surgery in patients with congenital myopathies and congenital muscular dystrophies: case series and review of the literature. *J Oral Maxillofac Surg* 2016;74:601-609.
- Georgiakaki I, Kiliaridis S. Intensive chewing and chewing training on masseter muscle thickness. *J Dent Res* 1998;77:1018.
- Guimaraes AS, Carlsson GE, Marie SK. Bite force and handgrip force in patients with molecular diagnosis of myotonic dystrophy. *J Oral Rehabil* 2007;34:195-200.
- Harper PS. *Myotonic dystrophy*. London: WB Saunders Co; 2001.
- He T, Stavropoulos D, Hagberg C, Hakeberg M, Mohlin B. Effects of masticatory muscle training on maximum bite force and muscular endurance. *Acta Odontol Scand* 2013;71:863-869.
- Ingervall B, Bistanis E. A pilot study of the effect of masticatory muscle training on facial growth in long-face children. *Eur J Orthod* 1987;9:15-23.
- Kaufman J, Friedman JM, Sadowsky D, Harris J. Myotonic dystrophy: surgical and anesthetic considerations during orthognathic surgery. *J Oral Maxillofac Surg* 1983;41:667-671.
- Kawazoe Y, Kobayashi M, Tasaka T, Tamamoto M. Effects of therapeutic exercise on masticatory function in patients with progressive muscular dystrophy. *J Neurol Neurosurg Psychiatry* 1982;45:343-347.
- Kiliaridis S, Engvall M, Tzakis MG. Ultrasound imaging of the masseter muscle in myotonic dystrophy patients. *J Oral Rehabil* 1995;22:619-625.
- Kiliaridis S, Katsaros C. The effects of myotonic dystrophy and Duchenne muscular dystrophy on the orofacial muscles and dentofacial morphology. *Acta Odontol Scand* 1998;56:369-374.
- Kiliaridis S, Lyka I, Friede H, Carlsson GE, Ahlqvist M. Vertical position, rotation, and tipping of molars without antagonists. *Int J Prosthodont* 2000;13:480-486.
- Kiliaridis S, Mejersjö C, Thilander B. Muscle function and craniofacial morphology: a clinical study in patients with myotonic dystrophy. *Eur J Orthod* 1989;11:131-138.
- Kiliaridis S, Tzakis MG, Carlsson GE. Effects of fatigue and chewing training on maximal bite force and endurance. *Am J Orthod Dentofacial Orthop* 1995;107:372-378.
- Liou EJ, Huang CS, Chen YR, Figueroa AA. Validity of using fixation screws/wires as alternative landmarks for cephalometric evaluation after LeFort I osteotomy. *Am J Orthod Dentofacial Orthop* 1998;113:278-292.
- Manzon S, Philibert R. Orthognathic surgery in a patient with myotonic dystrophy: review of the literature and report of a case. *J Oral Maxillofac Surg* 2007;65:2575-2579.
- Marik PK, Hoag JA. Self-concept in youth with congenital facial differences: Development and recommendations for medical providers. *Pediatr Dermatol* 2012;29:549-554.
- Mercier J, Bennani F, Ferri J, Piot B. Maxillofacial manifestations of Steinert's myotonic dystrophy: clinical and therapeutic aspects. *Rev Stomatol Chir Maxillofac* 1995;96:74-82.
- Müller H, Punt-van Manen JA. Maxillo-facial deformities in patients with dystrophia myotonica and the anaesthetic implications. *J Maxillofac Surg* 1982;10:224-228.
- Nozaki S, Kawai M, Shimoyama R, Futamura N, Matsumura T, Adachi K, Kikuchi Y. Range of motion exercise of temporomandibular joint with hot pack increases occlusal force in patients with Duchenne muscular dystrophy. *Acta Myol* 2010;29:392-397.
- Odman C, Kiliaridis S. Masticatory muscle activity in myotonic dystrophy patients. *J Oral Rehabil* 1996;23:5-10.
- Phillips C, Beal KN. Self-concept and the perception of facial appearance in children and adolescents seeking orthodontic treatment. *Angle Orthod* 2009;79:12-16.
- Portelli M, Matarese G, Militi A, Nucera R, Triolo G, Cordasco G. Myotonic dystrophy and craniofacial morphology: clinical and instrumental study. *Eur J Paediatr Dent* 2009;10:19-22.
- Russell SH, Hirsch NP. Anaesthesia and myotonia. *Br J Anaesth* 1994;72:210-216.
- Solano-Hernández B, Antonarakis GS, Scolozzi P, Kiliaridis S. Combined orthodontic and orthognathic treatment for the correction of skeletal anterior open-bite malocclusion: a systematic review on vertical stability. *J Oral Maxillofac Surg* 2013;71:98-109.
- Staley RN, Bishara SE, Hanson JW, Nowak AJ. Craniofacial development in myotonic dystrophy. *Cleft Palate Craniofac J* 1992;29:456-462.
- Suda N, Matsuda A, Yoda S, Ishizaki T, Higashibori N, Kim F, Otani-Saito K, Ohyama K. Orthodontic treatment of a case of Becker muscular dystrophy. *Orthod Craniofac Res* 2004;7:55-62.
- Thind BS, Turbill EA. Orthodontic camouflage treatment of Class II division 1 malocclusion in a patient with myotonic dystrophy. *Int J Orthod Milwaukee* 2015;26:55-58.
- Tieleman AA, Vinke A, van Alfen N, van Dijk JP, Pillen S, van Engelen BG. Skeletal muscle involvement in myotonic dystrophy type 2. A comparative muscle ultrasound study. *Neuromuscul Disord* 2012;22:492-499.
- Turner C, Hilton-Jones D. Myotonic dystrophy: diagnosis, management and new therapies. *Curr Opin Neurol* 2014;27:599-606.
- Umemoto G, Nakamura H, Oya Y, Kikuta T. Masticatory dysfunction in patients with myotonic dystrophy (type 1): a 5-year follow up. *Spec Care Dentist* 2009;29:210-214.
- Van Bruggen HW, van den Engel-Hoek L, Steenks MH, van der Bilt A, Bronkhorst EM, Crueters NH, de Groot IJ, Kalaykova SI. Fighting against disuse of the masticatory system in Duchenne muscular dystrophy: a pilot study using chewing gum. *J Child Neurol* 2015;30:1625-1632.
- Zanotelli E, Yamashita HK, Suzuki H, Oliveira AS, Gabbai AA. Temporomandibular joint and masticatory muscle involvement in myotonic dystrophy: a study by magnetic resonance imaging. *Oral Surg Oral Med Oral Pathol Oral Radiol Endod* 2002;94:262-271.