

Clinical antibacterial effectiveness Healozone Technology after incomplete caries removal



A. Libonati*, V. Di Taranto**, A. Mea**, E. Montemurro**, G. Gallusi**, V. Angotti**, R. Nardi**, L. Paglia***, G. Marzo****, V. Campanella**

*Department of Surgical Sciences, Dental School Catholic University of Our Lady of Good Counsel of Tirane, Tirane, Albania

**Department of Clinical and Translational Medicine, Dental School, University of Rome "Tor Vergata", Rome, Italy;

***Department of Paediatric Dentistry, Istituto Stomatologico Italiano (ISI), Milan, Italy;

****Department of Life, Health and Environmental Sciences, Dental School, University of L'Aquila, L'Aquila, Italy

e-mail: vincenzo.campanella@uniroma2.it

DOI 10.23804/ejpd.2019.20.01.14

Abstract

Aim Aim of this study was to evaluate the local effects of ozone gas on bacteria present within deep carious lesions after selective caries excavation.

Materials and methods The present study included 75 patients who had at least two Class I caries with deep lesion D2 and/or D3. The cavities were divided into 2 groups: the ozone group received treatment with Healozone X4, while the control group did not receive any treatment. Dentin samples were taken from both groups using two sterile multi-blade drills at 800 rpm without irrigation. The drills were then stored in separate tubes, each containing 5ml of RTF (Reduced Transport Fluid) and placed in culture for the next two hours. A total microbial count of the CFU of *Streptococcus Mutans* and *Lactobacillus* was performed.

Conclusions From the analysis of data on the dentin samples treated with ozone, there is a decrease in the bacterial load present in the infected carious dentin.

Introduction

Dental caries is a multifactorial disease linked to the interaction of four main factors: the bacterial flora (composed mainly of microorganisms that produce organic acids), the host (the quality and the shape of the tooth, the shape of the dental arch, characteristics of saliva, oral hygiene, type of diet and ability to develop an immune response both at the systemic and local level), substrates for microorganisms (such as carbohydrates contained in secretions and foods), and time (relatively long for decalcification and short for remineralisation of hard tissues).

The carious microorganisms have specific properties such as the ability of colonising the tooth surface, producing acid metabolites from food carbohydrates' fermentation, surviving in the presence of high concentrations of organic acids and synthesising extracellular polysaccharides from food carbohydrates [Struzycka, 2014].

Despite the spread of the principles of dietary, hygienic and fluorine prevention, which had led to a significant reduction in the incidence of caries, the frequency of this disease is increasing probably in relation to migratory phenomena and the conditions of social vulnerability of a part of the population [Monteagudo et al., 2015].

Treatment of caries entails removal of the carious tissue and the subsequent replacement of the missing tooth part with filling materials.

Furthermore, if the process is at an advanced stage, it may also be necessary to perform an endodontic treatment with further weakening of the dental structure, which may require more invasive conservative restorations or prosthetic restorations. All of this results in an increase in treatment costs that the healthcare system is often unable to sustain, and which therefore determine the exclusion of such therapies from essential levels of care [Maltz et al., 2012].

The phase of carious dentin removal, preliminary to subsequent filling, is crucial because a more conservative technique can limit the frequency of pulp involvement and the need for more invasive, longer and consequently more expensive therapies. Therefore, a procedure is proposed that entails partial removal of the carious tissue in a single session, thus avoiding exposure of the pulp and preserving a greater

KEYWORD Ozone, Antibacterial effect, Dentin, Incomplete caries removal.

PATIENT SAMPLE		
GENDER AND AGE		
Value	male	female
Patients	40	35
Mean age	48,3	47,8
Standard deviation	13,45	15,23

TABLE 1 Data of the sample.

amount of dental tissue [Mount, 2003].

“Minimally invasive” dentistry is a widely diffused concept that entails the selective removal of the infected or irreversibly denatured dentin and preservation of healthy or potentially remineralisable dentinal tissue. However, the exact amount of dentin that has to be removed is not easily quantifiable and it depends on the operator [Lennon et al., 2007; Thompson et al., 2008].

In order to simplify and standardise caries removal procedures, so-called self-limiting excavation techniques and tools have recently been introduced, such as ceramic-type rosettes, mounted on low-speed handpieces, useful for the selective removal of caries (CeraBur K1SM, Komet-Brasseler, Lemgo, Germany), or oscillating tungsten carbide tips (Cariex sistema, Kavo, Biberach, Germany) [Dammachke et al., 2006; Dammachke et al., 2008]. Despite this, even today conventional treatments require complete removal of all carious tissue before carrying out the restoration. There is also a two-stage treatment that involves re-entry and complete removal of carious dentin [Ritter et al., 2012]. The debate is whether or not to leave infected/affected dentin under the restoration, since even the complete removal of dentin does not prevent the permanence of pathogens under the restoration. In choosing the most appropriate method, in addition to the important aspect of sparing healthy or potentially remineralisable tissue, even the time required to perform the procedure is of great interest for both the operator and the patient. Partial removal of carious dentin shows a statistically significant improvement in maintaining the viability of the pulp compared to the total two-step excavation technique after a 2-year follow-up period [Weerheijm et al., 1999]. No adverse events related to demineralised dentin left on the wall of the pulp cavity are observed.

In the last decade, ozone has been widely used in restorative dentistry [D’Amario et al., 2015], paediatric dentistry [Tecco et al., 2014] and endodontics [Libonati et al., 2018; Libonati et al., 2018]. In fact, ozone in the gaseous state binds to the cell wall, specifically to the double lipid layer, and oxidises nucleic acids and amino acids, causing cell lysis [Ximenes et al., 2017]. It has also been proven that ozone is able to remineralise dentin lesions, degrading the caries molecules and opening the dentinal canals, in such a way as to favour remineralisation, thus increasing the penetration of the remineralising agents [Rao et al. Malhotra 2011; Yazicioglu and Ulukapi, 2014; Samuel et al., 2016]. Based on the studies cited in a review [Burke, 2012], it can be said that complete removal of infected dentin in deep carious lesions [Scorzetti et al., 2013; Cianetti et al., 2017; Paglia et al., 2016], is not required, and the success of the treatment is conditional to a restoration able to effectively seal the lesion from the oral environment.

The present study aimed at assessing the possibility of

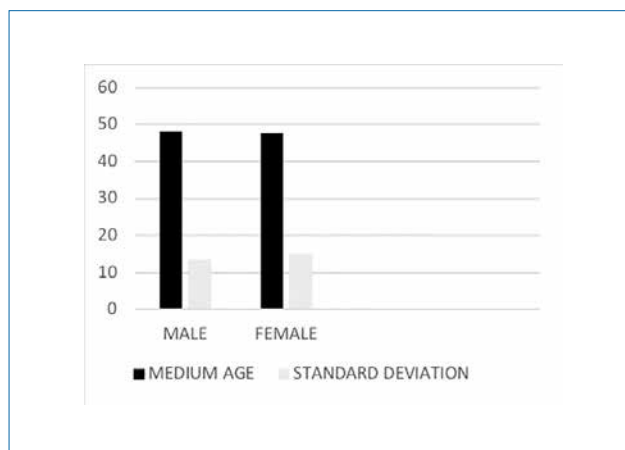


FIG. 1 Data of the sample.

reducing the microbial load of deep carious lesions through the use of ozone therapy [Azarpazhooh et Limeback, 2008; Nogales et al., 2008; Saini, 2011].

Materials and methods

The present study evaluates the effectiveness of the Healozone X4 device in reducing the microbial load of active Class I caries lesions on permanent teeth. We analysed:

1. The microbial load of deep carious lesions;
2. The microbial load of deep carious lesions after treatment with Healozone X4 [Brazzelli et al., 2006; Rodrigues et al., 2011].

After collection of carious tissue samples and subsequent culture on a selective plate for Streptococcus Mutans and Lactobacillus' growth [Mummolo et al. 2014; Chaves et al., 2017; Kronic et al., 2018; Sancakli et al., 2018], the microbial count was performed.

This study was performed at the UOSD-Emergency Dental Department of the unit of Conservative, Restorative and Endodontic Dentistry of the Tor Vergata Polyclinic, Rome, Italy.

The inclusion criteria were:

- Adult age;
- Presence of at least two Class I carious lesions of grade D2 and/or D3.

The exclusion criteria were:

- Psychiatric conditions;
- Treatment with psychotropic and/or narcotic drugs;
- Pregnancy status;
- Local anesthetics allergy.

We proceeded by applying the parameters necessary for sample determination (mean, effect size, standard deviation) for which a number of 75 patients is considered sufficient (test power of 80% and statistical significance equal to 0.05%).

The study included 75 subjects, 40 males (53.3%) and 35 females (46.7%) with a mean age of 46.3 ± 18.48 years and 49.7 ± 19.23 years respectively (Table 1; Fig. 1).

In this study, HealOzone X4 is used for ozone therapy in dentistry in “High dosage” mode for 60 seconds.

This device produces ozone from a special O₂ bottle and turns it into ozone at a concentration of 32 g/m³. From the silicone cap, ozone is delivered to the target area, while the excess is converted into pure oxygen.

For the subsequent removal of carious dentin, it was employed a SmartBursII drill (SS White Dental, Lakewood, NJ).

Anamnesis and informed consent

During the first visit, the patient filled the anamnestic questionnaire and signed the informed consent for this trial. On intraoral examination, according to the inclusion criteria, the patient had to present at least 2 class I carious lesions on teeth positive to cold testing. Moreover, a bite-wing x-ray was performed in order to assess the extent of the carious lesion; only lesions affecting at least 2/3 of the pulp chamber were selected.

Sample collection and tooth restoration

After performing local anaesthesia [Campanella et al., 2018], each tooth was isolated by rubber dam, in order to minimise contamination during dentin sample collection.

A diamond bur mounted on a turbine was used for enamel removal.

The sample consisted of 75 patients with at least two suitable carious lesion, which were treated in two appointments to collect both samples.

The sample was divided into two groups:

1. The control group, which did not receive ozone treatment (No. 75);
2. The ozone group, which received ozone treatment for 60 seconds prior to sample collection (No. 75).

For both groups, samples of dentin were taken from the coronal carious portion of the cavity, using 2 tungsten multilayer sterile burs (H1S 018, Komet Dental, Lemgo, Germany) kept in sterile saline solution and mounted on a micromotor handpiece at 800 rpm without irrigation for each tooth. To avoid exceeding 2/3 of the thickness of the carious dentin, the working depth was estimated by calibrating the drill on the bite-wing radiograph.

The drills used for dentin removal were placed inside a tube containing 5 ml of RTF (Reduced Transport Fluid) and placed in culture for the next two hours.

After the removal, complete caries removal was achieved using a Smart Burr II drill (SS White Dental, Lakewood, NJ) mounted on a micromotor at 10,000 rpm, under irrigation.

The cavity was restored with direct technique using the following adhesive procedures.

1. For teeth treated with ozone pretreatment with antioxidant (10% sodium ascorbate for 10 minutes) was performed.
2. Etching with 37% orthophosphoric acid for 15 s on dentin and 30 s on enamel (Total Etch, Ivoclar).
3. Application of a fourth-generation adhesive (Prime & Bond NT, Dentsply) [Gallusi et al., 2009; Ballesio et al., 2012].
4. Restoration with microhybrid composite (Enamel Plus HRI, Micerium) using the incremental technique [Libonati et al., 2011].
5. A bitewing radiograph was taken at completion of

restoration.

The patients are recalled after 6 months for a follow-up and radiographic checkup by means of a periapical x-ray in order to record any failures of the procedure.

Microbiological analysis

The collected samples were dispersed by sonication for 5s, centrifuged for 15s, diluted 10 times in RTF; 25 ml of this dilution were grown in duplicate in the culture medium.

Isolation of Streptococcus Mutans occurred on Mitis agar supplemented with 20% sucrose and bacitracin 0.2 units / ml.

Isolation of Lactobacillus occurred on Rogosa selective Lactobacillus agar.

The total CFU count was performed on BHI supplemented with 5% sheep blood and enriched with vitamin K.

Streptococcus Mutans was incubated in an anaerobic habitat at 37°C for 48 h. The Streptococcus Mutans count was performed after morphological recognition and confirmed with microbiological tests.

Rogosa SL agar was incubated in an aerobic habitat at 37° C for 72h. The Lactobacillus microbial count was performed using the "pour-plate" technique: anaerobic BHI incubation for 120 h in an atmosphere containing 5% CO₂ and 95% N₂ in order to determine the total anaerobic count. The aerobic incubation of the BHI was also performed for 48 h in order to determine the total aerobic count. The limit per sample was 200 CFU.

Statistical analysis

All data were initially entered into an EXCEL database (Microsoft, Redmond, Washington – United States) and the analysis was performed using the Statistical Package for the Social Sciences Windows, version 15.0 (SPSS, Chicago, Illinois, USA). Descriptive statistics consist of the mean ± standard deviation for parameter with normal distributions (Table 2,

Teeth	Conventional Treatment	Healozone X4 Treatment
1.6	10	12
2.6	9	11
3.6	8	10
4.6	13	12
1.7	8	7
2.7	7	9
3.7	12	4
4.7	8	10
	75	75

TABLE 2 Distribution of the type of treatment.

	SM(TC)	LT(TC)	SM (OZ)	LT(OZ)
N	75	75	75	75
Mean	49746,67	39640,00	40840,00	29600,00
Std. Deviation	26594,601	23686,945	26568,646	18473,502
Median	51000,00	32000,00	31000,00	26000,00
Minimum	9000	5000	4000	7000
Maximum	98000	90000	96000	81000

TABLE 3 Data analysis.

		grt	N	Mean	sd	%change	Minimum	Maximum
	gr							
SM	0	TC	75	49746,7	26594,6		9000	98000
	1	OZ	75	40840,0	26568,6	-17,904	4000	96000
	Total		150	45293,3	26866,4		4000	98000
LT	0	TC	75	39640,0	23686,9		5000	90000
	1	OZ	75	29600,0	18473,5	-25,328	7000	81000
	Total		150	34620,0	21760,3		5000	90000

TABLE 4 Comparison among groups.

	Sum of Squares	df	Mean Square	F	Sig.	
SM	Between Groups	2974826666,667	1	2974826666,667	4,210	,042
	Within Groups	104574266666,667	148	706582882,883		
	Total	107549093333,334	149			
LT	Between Groups	3780060000,000	1	3780060000,000	8,378	,004
	Within Groups	66773280000,001	148	451170810,811		
	Total	70553340000,001	149			

TABLE 5 Comparison among groups.

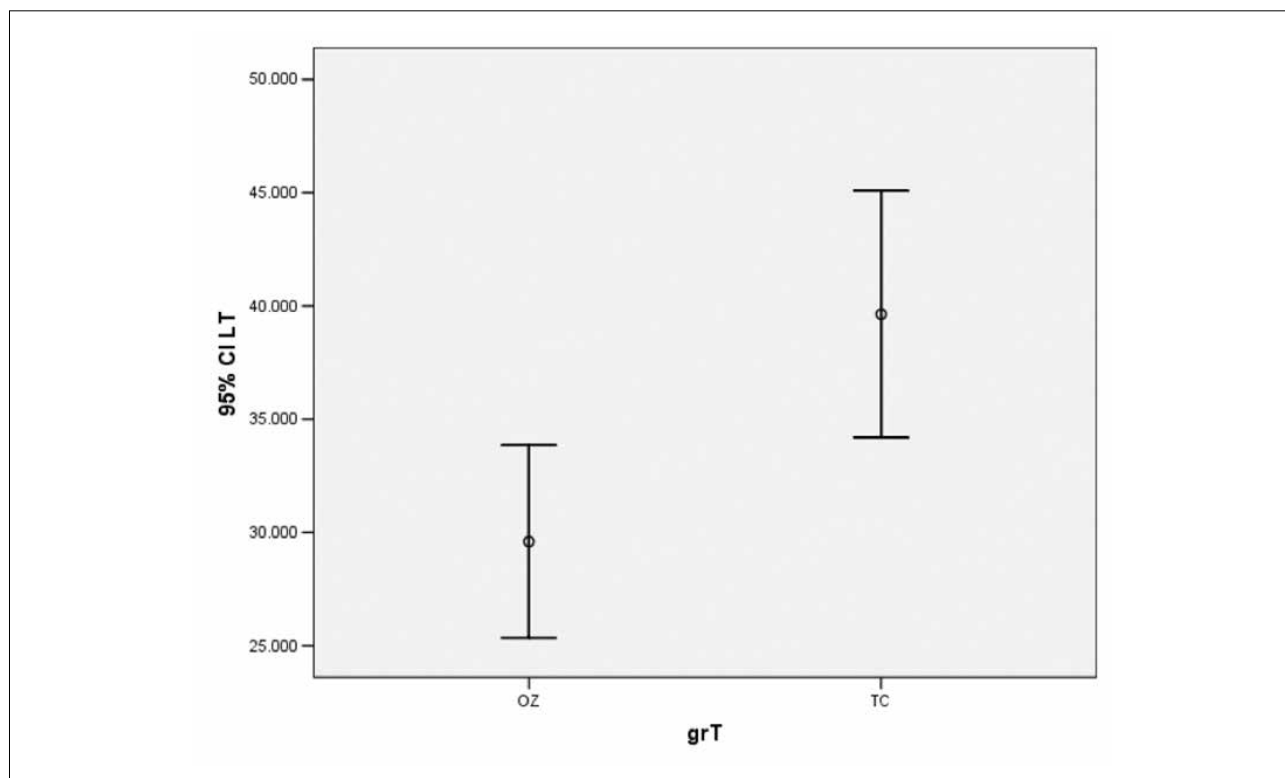


FIG. 2 Significant reduction of bacterial species.

3) (after confirmation with histograms and the Kolmogorov-Smirnov test). Comparison among groups (Table 4, 5) was

performed with the one-way ANOVA for normal variables. A p value of <0.05 was considered statistically significant.

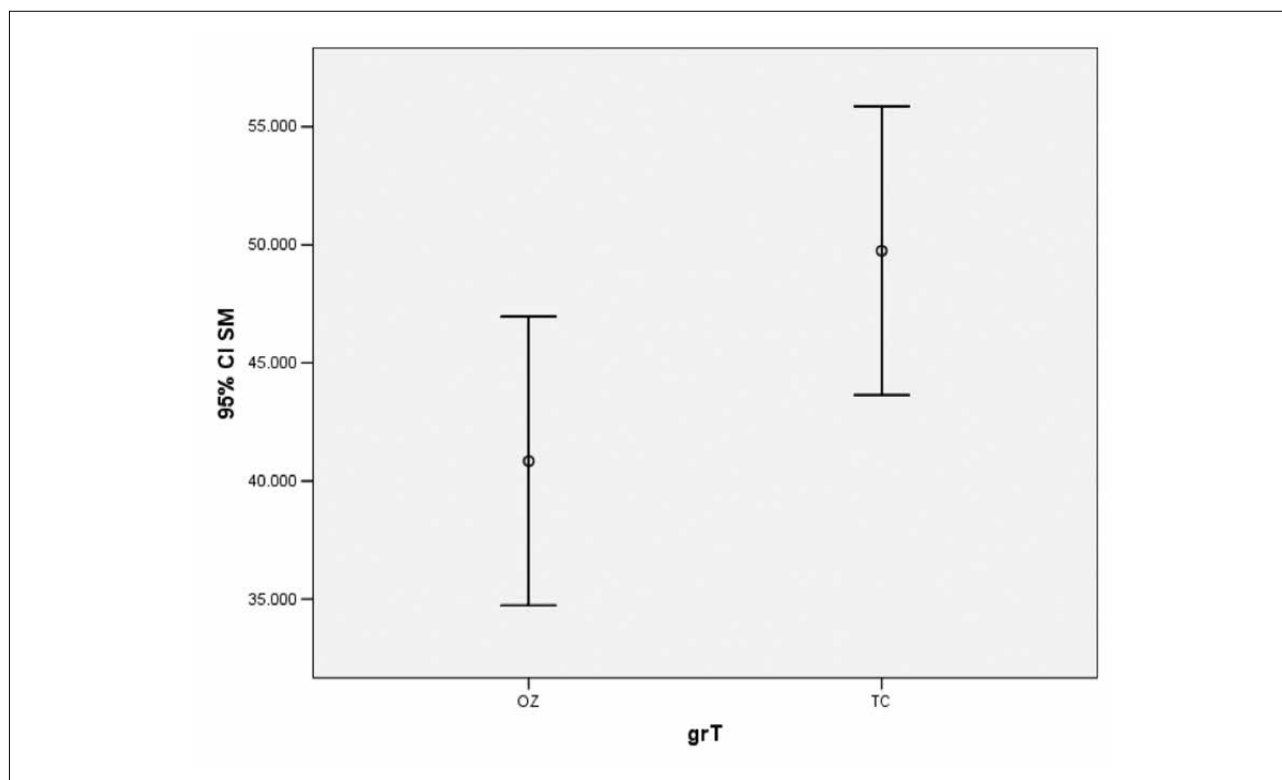


FIG. 3 Significant reduction of bacterial species.

Results

Table 2 shows the distribution of the type of treatment performed (conventional and with HealOzone X4).

After ozone treatment, the CFU count (Table 3) for Streptococcus Mutans decreased on average by 17.90% (Table 4) (40840.00), with a level of significance of 0.042.

Similarly, for Lactobacillus there was a reduction in CFU which was on average higher than that of Streptococcus Mutans, reaching 25.32% (Table 4) (29600.00) and a significance level equal to 0.004.

The one way ANOVA test (Table 5, Fig. 2, 3) showed the existence of a statistically significant difference in the reduction of bacterial species, especially for Lactobacillus.

Discussion

Ozone appears to have a great indication in paediatric dentistry, being painless and not requiring local anaesthesia. It provides an effective improvement in the atraumatic restoration technique (ART) with minimal excavation, thus it is especially valid for the painless treatment of caries of deciduous teeth in very small or difficult to treat children.

This study was developed to investigate the ozone-induced CFU reduction of Streptococcus Mutans and Lactobacillus since several studies reported large quantities of these bacterial species in dental caries of deciduous and permanent teeth [Ximenes et al., 2017].

The CFU count for the tested bacteria underwent a statistically significant reduction after the single application of 32g/m³ of ozone for 60 seconds (as recommended by manufacturer), with better results for Lactobacillus.

This treatment shows a significant reduction in the CFU

of Streptococcus Mutans and Lactobacillus measured after culturing dentin samples. At the 6months recall visit, all treated patients did not show any caries recurrence, marginal infiltration or clinical symptoms [Concolino et al., 2007; Germano et al., 2013; Mummolo et al., 2014; Bernardi et al., 2016].

Conclusion

The caries excavation method has proven to be clinically effective. In fact, both the teeth belonging to the control group and those treated with ozone, did not require any retreatment at six-month follow-up.

The analysis of the microbiological data of untreated dentin samples and those treated with Healozone X4, shows that ozone treatment induces a significant decrease of the CFU of bacteria from infected carious dentin. This effect is more evident for Lactobacillus (change -25.328% and significance 0.004) than for Streptococcus Mutans (change -17.904% and significance 0.042). This study suggests that the application of ozone in deep caries, with a partial excavation of dentin, has an antibacterial effect, proven by the total count of CFU for both Lactobacillus and Streptococcus Mutans. These results show the microbiological effects of local application of ozone in deep cavities, opening an interesting perspective towards the use of ozone as an adjunct treatment in minimally invasive caries excavation.

Disclaimer

The Authors declare that they are free of conflicts of interest.

References

- Azarapazhooh A, Limeback H. The application of ozone in dentistry: a systematic review of literature. J Dent

- 2008;36(2):104-16.
- › Ballesio I, Angotti V, Gallusi G, Libonati A, Tecco S, Marzo G, Campanella V. Durability of adhesion between an adhesive and post-space dentin: push-out evaluation at one and six months. *Int J Adhes Adhes* 2012;38:75-78.
 - › Bernardi S, Mummolo S, Ciavarella LM, Li Vigni M, Continenza MA, Marzo G. Cone beam computed tomography investigation of the antral artery anastomosis in a population of Central Italy. *Folia Morphol (Warsz)* 2016; 75(2): 149-153.
 - › Brazzelli M, McKenzie L, Fielding S, Fraser C, Clarkson J, Kilonzo M, Waugh N. Systematic review of the effectiveness and cost-effectiveness of HealOzone for the treatment of occlusal pit/fissure caries and root caries. *Health Technol Assess* 2006;10(16):iii-iv, ix-80.
 - › Burke FJ. Ozone and caries: a review of the literature. *Dent Update* 2012; 39(4):271-2, 275-8.
 - › Campanella V, Libonati A, Nardi R, Angotti V, Gallusi G, Montemurro E, D'Amaro M, Marzo G. Single tooth anesthesia versus conventional anesthesia: a cross-over study. *Clin Oral Investig* 2018.
 - › Chaves RM, Estrela C, Cardoso PC, de J Barata T, de Souza JB, de Torres EM, Estrela CR, Magalhaes AP, Lopes LG. Ozone gas effect on mineral content of dentin exposed to streptococcus mutans biofilm: an energy-dispersive x-ray evaluation. *J Contemp Dent Pract* 2017;18(4):265-269.
 - › Cianetti S, Lombardo G, Lupatelli E, Rossi G, Abraha I, Pagano S, Paglia L. Dental caries, parents educational level, family income and dental service attendance among children in Italy. *Eur J Paediatr Dent* 2017;18(1):15-18.
 - › Concolino P, Cecchetti F, D'Autilia C, Santonocito C, Di Stasio E, Zuppi C, Ar-curi C, Deli G, Giardina B, Capoluongo E, Ameglio F. Association of periodontitis with GSTM1/GSTT1-null variants- a pilot study. *Clin Biochem* 2007;40(13-14):939-945.
 - › D'Amaro M, De Angelis F, Vadini M, Marchili N, Mummolo S, D'Arcangelo C. Influence of repeated preheating procedure on mechanical properties of three resin composite. *Oper Dent* 2015;40(2):181-189.
 - › Dammaschke T, Rodenberg TN, Schafer E, Ott KH. Efficiency of polymer bur SmartPrep compared with conventional tungsten carbide bur in dentin caries excavation. *Oper Dent* 2006; 31(2):256-60.
 - › Dammaschke T, Vesnic A, Schafer E. In vitro comparison of ceramic burs and conventional tungsten carbide bur burs in dentin caries excavation. *Quintessence Int* 2008;39(6):459-9.
 - › Gallusi G, Galeano P, Libonati A, Giuca MR, Campanella V. Evaluation of bond strength of different adhesive systems: Shear and Microtensile Bond Strength Test. *Oral Implantsol* 2009;2(4):19-25.
 - › Germano F, Bramanti E, Arcuri C, Cecchetti F, Cicciù M. Atomic force micro-scopy of bacteria from periodontal subgingival biofilm: Preliminary study results. *Eur J Dent* 2013;7(2):152-158.
 - › Kronic J, Stojanovic N, Durick L, Roganovic J, Popovic J, Simic I, Stojic D. Clinical antibacterial effectiveness and biocompatibility of gaseous ozone after incomplete caries removal. *Clin Oral Investig* 2018;Jun 1.
 - › Lennon AM, Attin T, Buchalla W. Quantity of remaining bacteria and cavity size after excavation with FACE, caries detector dye and conventional excavation in vitro. *Oper Dent* 2007;32-3:236-241.
 - › Libonati A, Di Taranto V, D'Agostini C, Santoro MM, Di Carlo D, Ombres D, Gallusi G, Favalli C, Marzo G, Campanella V. Comparison of coronal leakage of different root canal filling techniques: an ex vivo study. *J Biol Regul Homeost Agents* 2018; 32(2): 397-405.
 - › Libonati A, Marzo G, Klinger FG, Farini D, Gallusi G, Tecco S, Mummolo S, De Felici M, Campanella V. Embriotoxicity assays for leached components from dental restorative materials. *Reprod Biol Endocrinol* 2011;9:136.
 - › Libonati A, Montemurro E, Nardi R, Campanella V. Percentage of Gutta-percha-filled areas in canals obturated by 3 different techniques with and without the use of endodontic sealer. *J Endod* 2018;44(3):506-509.
 - › Maltz M, Henz SL, de Oliveira EF, Jardim JJ. Conventional caries removal and sealed caries in permanent teeth: A microbiological evaluation. *J Dent* 2012;40(9):776-82.
 - › Monteagudo C, Téllez F, Heras-González L, Ibañez-Peinado D, Mariscal-Arcas M, Olea-Serrano F. School dietary habits and incidence of dental caries. *Nutr Hosp* 2015;32(1):383-8.
 - › Mount GJ. Minimal intervention dentistry: rationale of cavity design. *Oper Dent* 2003; 28(1):92-9.
 - › Mummolo S, Ortu E, Necozione S, Monaco A, Marzo G. Relationship between mastication and cognitive function in elderly in L'Aquila. *Int J Clin Exp Med* 2014; 7(4): 1040-1046.
 - › Mummolo S, Tieri M, Tecco S, Mattei A, Albani F, Giuca MR, Marzo G. Clinical evaluation of salivary indices and levels of Streptococcus mutans and Lacto-bacillus in patients treated with Occluso-o-Guide. *Eur J Paediatr Dent* 2014;15(4):367-370.
 - › Nogales CG, Ferrari PH, Kantorovich EO, Large-Marques JL. Ozone therapy in medicine and dentistry. *J Contemp Dent Pract* 2008;9(4):75-84.
 - › Paglia L, Scaglioni S, Torchia V, De Cosmi V, Moretti M, Marzo G, Giuca MR. Familial and dietary risk factors in Early Childhood Caries. *Eur J Paediatr Dent* 2016;17(2):93-9.
 - › Rao A, Malhotra N. The role of remineralizing agents in dentistry: a review. *Compend Contin Educ Dent* 2011;32(6):26-33.
 - › Ritter AV, Browning WD, Swift EJ Jr. Critical appraisal. Partial caries excavation. *J Esthet Restor Dent* 2012;24(2):148-52.
 - › Rodrigues PC, Souza JB, Soares CJ, Lopes LG, Estrela C. Effect of ozone application on the resin-dentin microtensile bond strength. *Oper Dent* 2011;36(5):537-44.
 - › Saini R. Ozone therapy in dentistry: A strategic review. *J Nat Sci Biol Med* 2011;2(2):151-3.
 - › Samuel SR, Dorai S, Khatri SG, Patil ST. Effect of ozone to remineralize initial enamel caries: in situ study. *Clin Oral Investig* 2016;20(5):1109-13.
 - › Sancakli HS, Siso SH, Yildiz SO, Gokce YB. Antibacterial effect of Surface Pre-treatment Techniques against Streptococcus Mutans. *Niger J Clin Pract* 2018;21(2):170-175.
 - › Scorzetti L, Marcattili D, Pasini M, Mattei A, Marchetti E, Marzo G. Association between obesity and periodontal disease in children. *Eur J Paediatr Dent* 2013;14(3):181-4.
 - › Struzycska I. The oral microbiome in dental caries. *Pol J Microbiol* 2014;63(2):127-35.
 - › Tecco S, Lacarbonara M, Dinioi MT, Gallusi G, Marchetti E, Mummolo S, Campanella V, Marzo G. The retrieval of unerupted teeth in pedodontics: two case re-ports. *J Med Case Rep* 2014;8:334.
 - › Thompson V, Craig RG, Curro FA, Green WS, Ship JA. Treatment of deep carious lesions by complete excavation of partial removal: a critical review. *J Am Dent Assoc* 2008;139(6):705-12.
 - › Weerheijm KL, Kreulen CM, de Soet JJ, Groen HJ, van Amerongen WE. Bacterial counts in carious dentine under restorations: 2-years in vivo effects. *Caries Res* 1999;33(2):130-4.
 - › Ximenes M, Cardoso M, Astorga F, Arnold R, Pimenta LA, Viera RS. Antimicrobial activity of ozone and NaF-chlorhexidine on early childhood caries. *Braz Oral Res* 2017; 31:e2.
 - › Yazicioglu O, Ulukapi H. The investigation of non-invasive techniques for treating early approximal carious lesions: an in vivo study. *Int Dent J* 2014;64(1):1-11.